

**Original article:**

## **Role of uterine artery embolisation in the management of menorrhagia**

**Vivek Ukirde, Kishor Rajpal, Maunil Bhuta, Saurabh Joshi, Tanvi Modi**

Department of Radiology, Lokmanya Tilak Municipal General Hospital and Lokmanya Tilak Municipal Medical College, Sion, Mumbai, Maharashtra, India

Corresponding author: Dr Vivek Ukirde

---

### **Abstract**

Menorrhagia is defined as excessive loss of blood during the menstrual cycle, and is the most common gynaecological complaint of females of the reproductive age group presenting to the Department of Obstetrics and Gynaecology.

Fibroids are the most common cause of menorrhagia. The most common investigations performed to establish the etiology are- USG Pelvis, Hormonal tests, HSGs, D & C, hysteroscopy and rarely MR Pelvis. Management of menorrhagia includes medical management- hormonal / anti fibrinolytics, surgical management- D & C, myomectomy, hysterectomy. Uterine artery embolisation ( unilateral or bilateral ) is an effective management option for menorrhagia, as ascertained by our study.

Keywords : menorrhagia, fibroids, uterine artery embolisation.

---

### **Introduction**

Menorrhagia is the most common symptom for which females in child bearing age group are presented to gynaecologist. Causes of it are either organic (such as fibroids, adenomyosis, pelvic endometriosis, chronic tubo-ovarian masses) or functional (Due to disturbed hypothalamo-pituitary-ovarian axis)

Management primarily includes removal of cause of symptoms. If not possible then first Medical management comprising Hormonal- progestins, combination of progesterone and estrogen preparation, Danazol, clomiphene citrate and GnRH analog<sup>1</sup>; or prostaglandin synthetase inhibitor or antifibrinolytic agents are used. If medical treatment fails then surgical options (semi-invasive- invasive) considered. These include uterine curettage, endometrial ablation / resection, myomectomy and hysterectomy<sup>2</sup>. Percutaneous

transcatheter embolisation (minimally invasive) of bilateral uterine arteries is an established alternative option to conventional medical and surgical management of menorrhagia and rapidly gaining acceptance amongst patients and physicians. Uterine fibroid embolisation as the sole therapy has been established to be safe, effective and minimally invasive alternative to traditional therapies such as hysterectomy, myomectomy and hormonal therapy. Further advantages over surgical techniques include shorter recovery period, shorter hospitalisation and better cost-effectiveness<sup>3</sup>.

### **Aims and objectives**

To evaluate the role of uterine artery embolisation (UAE) in patients with menorrhagia in terms of

1. Reduction in quantity of bleeding during menstrual cycle.
2. Regularisation of menstrual cycle.

3. Reduction of pain during menstrual cycle.
4. Reduction in associated pressure symptoms
5. Patient satisfaction.

### **Materials and methods**

From Mar 2005 to Aug 2006, 21 patients (age range 08-44 years; mean age 33.3 years) referred from the Gynaecology and Obstetric department (outpatient and indoor) with symptoms related to menorrhagia were treated with selective arterial embolisation of the uterine arteries. We embolise patients using PVA particles of size 355-500 and 500-750 microns and patients respond well to UAE.[Fig 1]

### **Observations and results**

In all patients, both uterine arteries were cannulated and embolised hence technical success rate was 100%. The mean diameter of dominant fibroid in pre-embolisation stage was 9.3 cm which reduced to 6.1cm at 3 months and 3.3 cm at 6 months. All lesions show decreased vascularity on follow up examinations. 90% patients experienced symptom relief.

### **Discussion**

The mean age of the women was 33.3 years (most common age group being 31-40 years). Fibroid was the most common indication, Refractory vaginal bleeding was the dominant and main symptom in all women, followed by dysmenorrhoea. Bilateral embolisation of the uterine arteries [Fig 2] was successful in 21 (100%) women.

No major anatomic variations preventing the successful super-selective catheterisation [Fig 3] of

the bilateral uterine arteries were noted.

The mean diameter of dominant fibroid in pre-embolisation stage was 9.3 cm which reduced to 6.1 cm at 3 months and 3.3 cm at 6 months. About 10% of treated patients show no improvement of symptoms which corresponds to treatment failure. The failure of UAE can be described as early and late. The early failure covers technical failure (unsuccessful embolisation)<sup>4</sup>. The late failure represents persistence of symptoms for 6 months or more, often associated with large fibroids, adenomyosis and continued blood supply from the ovarian artery.

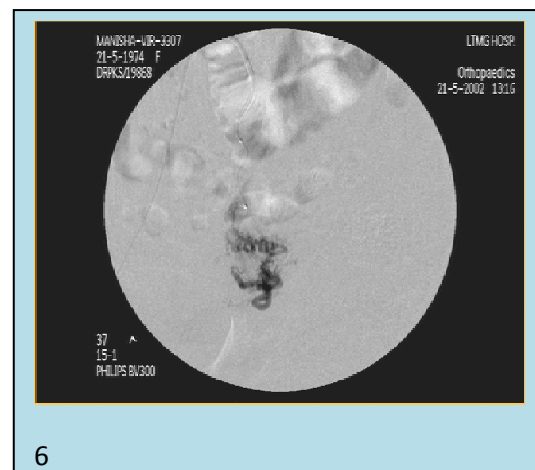
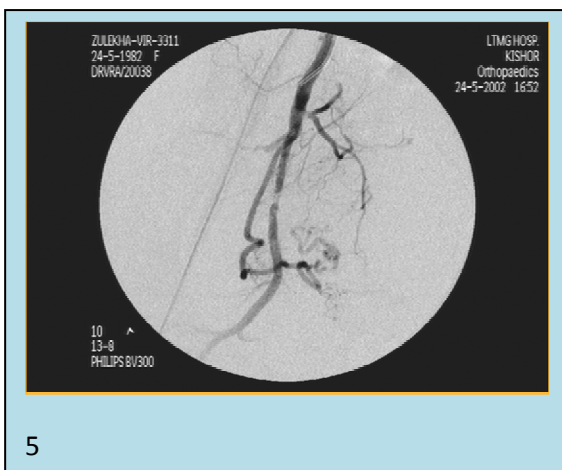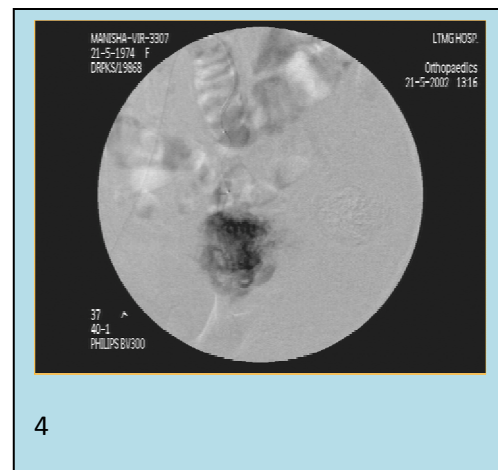
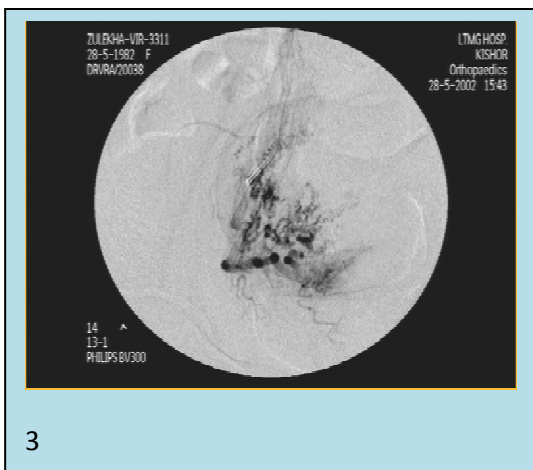
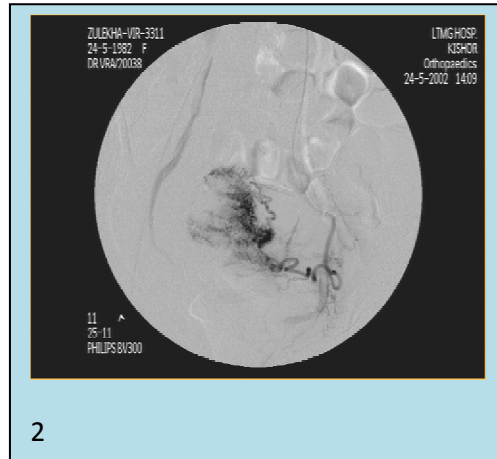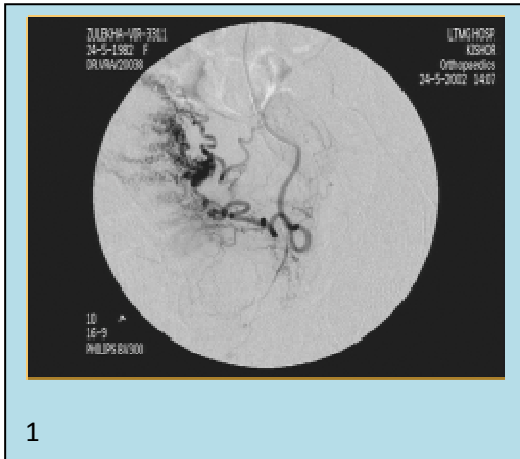Fluoroscopy time during UAE procedures is an important consideration because the ovaries are in the radiation field during the procedure<sup>5</sup>. In this study, the average fluoroscopy time (26 minutes). Pelvic pain is the most common side effect and complication during and after UAE. We observed the same but incidence was less compared to published articles<sup>6,7</sup>.

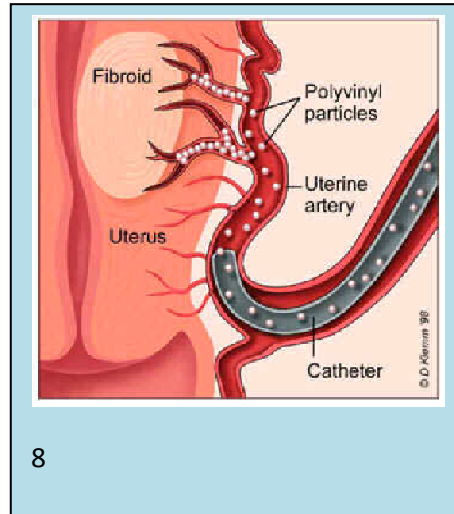
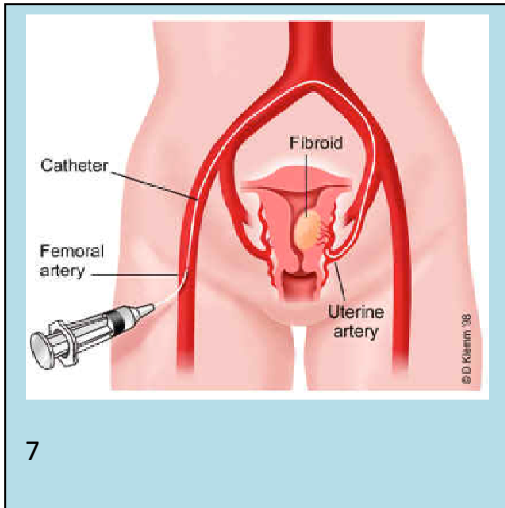
The mean post-procedural hospital stay in our study was 3.1 days. The serious complications like premature amenorrhoea due to ovarian failure though noted in literature yet not observed in our study, probably due to small study size and very few patients in peri-menopausal group. Similar observation i.e. premature loss of ovarian function was also noticed after hysterectomy. However this is relatively rare complication and most women resume normal menstruation after embolisation of the uterine arteries in 3 months<sup>8,9</sup>. Successful term pregnancy has been reported after bilateral uterine embolisation<sup>10</sup>.

**Conclusion**

Uterine artery embolisation is an effective treatment modality for patients suffering from menorrhagia with outcomes comparable to

conventional surgical methods and superlative to medical management, with minimum complications.





### References

1. Healy DL, Vollenhoven BJ. The role of GnRH agonists in the treatment of uterine fibroids. *Br J Obstet Gynaecol* 1992; 99:23-26.
2. Ravina J et al: Arterial Embolisation of Uterine Myomata: *J. Gynaecol. Obstet Biology Reproduction (Paris)* 2000; 24(3).272-5.
3. Robert A. Bucek, Stefan Puchner and Johannes Lammer; Mid- and Long-Term Quality-of-life Assessment in Patients Undergoing Uterine Fibroid Embolisation *AJR* 2006; 186:877-882.
4. Nicholson T. Outcome in patients undergoing unilateral uterine artery embolisation for symptomatic fibroids. *Clin Radiol* 2004; 59: 186-191.
5. Pinto et al; Uterine fibroids: Uterine Artery Embolisation vs Abdominal Hysterectomy for Treatment- A Prospective, Randomized, and Controlled Clinical Trial *Radiology* , 2003; 226:425-431.
6. Pelage et al ; Fibroid-related Menorrhagia: Treatment with Superselective Embolisation of the Uterine Arteries and Midterm Follow-up; *Radiology*. 2000; 215: 428-431.
7. Siskin G, Stainken B, Dowling K, Meo P, Ahn J, Dolen E. Outpatient uterine artery embolisation for symptomatic uterine fibroids: experience in 49 patients. *J Vasc Interv Radiol* 2000; 11: 305-311.
8. Pron et al; The Ontario Uterine Fibroid Embolisation Trial Part 2. Uterine fibroid reduction and symptom relief after uterine artery embolisation for fibroids; Volume 79, Issue 1, Pages 120-127, 2003; *Fertility and sterility*.
9. Siddle N, Sarrel P, Whitehead M. The effect of hysterectomy on the age at ovarian failure: identification of a subgroup of women with premature loss of ovarian function and literature review. *Fertil Steril* 1987; 47: 94-100.
10. Ravina JH, Bouret JM, Fried D, et al. Value of preoperative embolization of uterine fibroma: report of a multicenter series of 31 cases. *Contracept Fertil Sex* 1995; 23:45-49[Medline].